

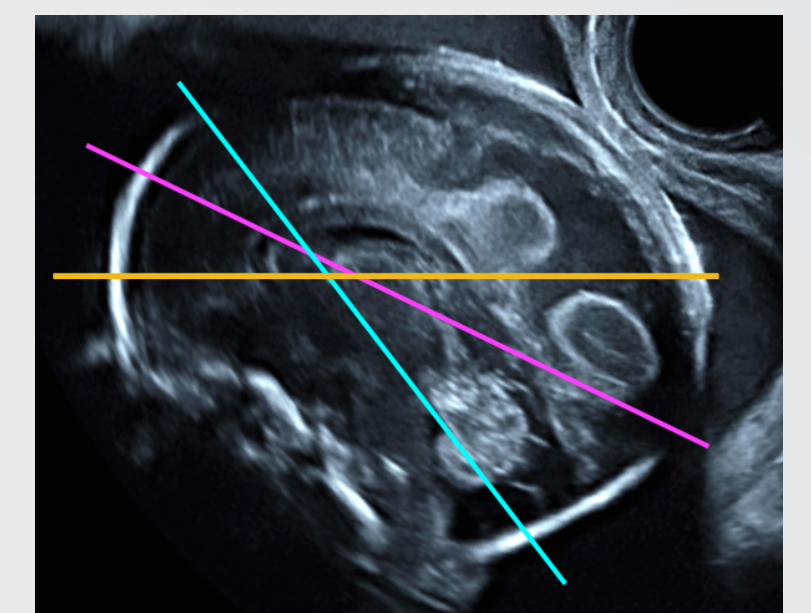
Fetal brain | From 22 to 32 weeks



Docteur Jean-Philippe Bault

CHU Bicêtre, CPDP Poissy Saint-Germain, Les Mureaux

	22 weeks	28 weeks	32 weeks
Sagittal Plane			
Axial Plane Biparietal Plane			
Axial Plane Ventricles Plane			
Axial Plane Posterior Fossa Plane			
Coronal Plane			



Axial Planes

- Biparietal diameter plane
- Lateral ventricles plane (plane of the atrial diameter measurement)
- Posterior fossa plane

LEGEND

- fh:** Frontal horns of lateral ventricles
- *:** Cavity of the septum pellucidum
- cf:** Crura of fornix
- t:** Thalami
- ca:** Cisterna ambiens
- sf:** Sylvian fissures
- lv:** Lateral ventricles
- o:** Fourth ventricle
- v:** Vermis
- tc:** Brain stem
- cm:** Cisterna magna
- Falx cerebri
- Corpus callosum
- Internal occipital fissure
- Third ventricle
- Cingulate fissure