

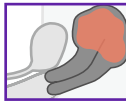
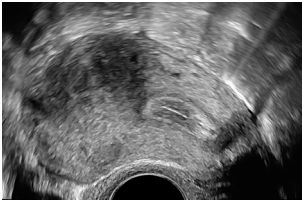
# The Pelvic Pain Patient

## Easy 5-Step Ultrasound Evaluation

Gernot Hudelist, MD, PD, MSc  
 Clinical Lecturer | Head, Certified Tertiary Referral Center for Endometriosis,  
 Hospital St. John of God, Vienna  
 Woman and Health Private Clinic, Vienna, Austria

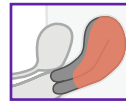
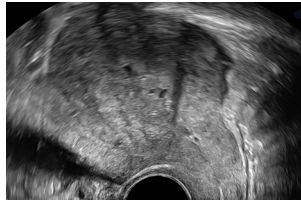
### 1. Uterus

#### Adenomyosis – Nodular



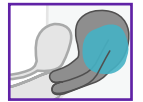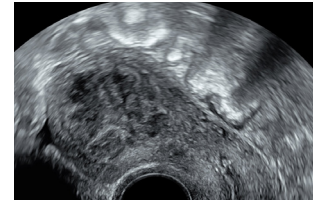
Asymmetry,  
 shadowing,  
 irregular perfusion

#### Adenomyosis – Diffuse



Ill-defined with  
 diffuse perfusion

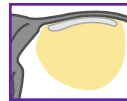
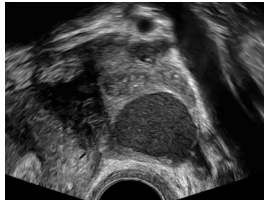
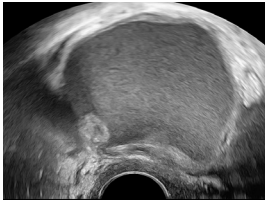
#### Fibroid



Round-shaped  
 with perfusion

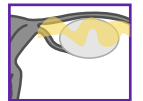
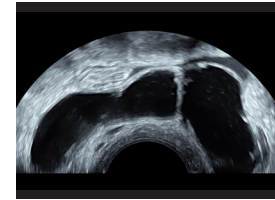
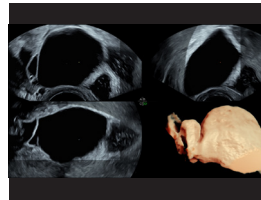
### 2. Adnexal Region

#### Endometrioma



Ground glass  
 appearance

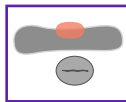
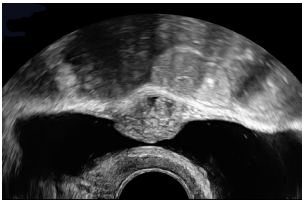
#### Hydrosalpinx



Irregular septae  
 characterized by  
 a “cogwheel sign”

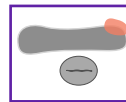
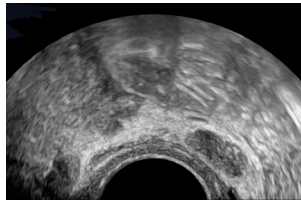
### 3. Urinary Bladder

#### Central Bladder – Deep Endometriosis



Transverse Plane

#### Lateral Bladder – Deep Endometriosis

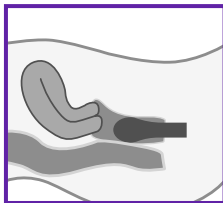


Transverse Plane

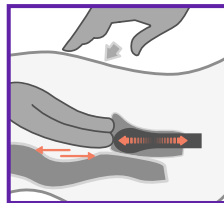
- Iso/hyperechoic
- Nodular
- Ill-defined border
- Disruption of muscular layer

### 4. Posterior Compartment Sliding Sign – Pod Obliteration

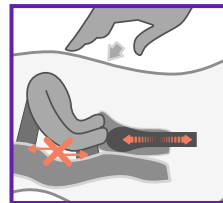
#### Neutral



#### Positive Sliding



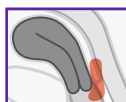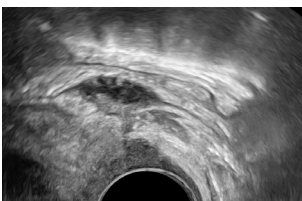
#### Negative Sliding



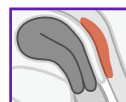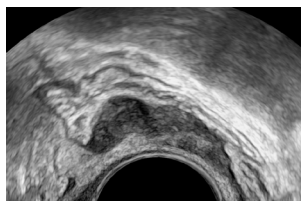
- Bimanual exam (optional)
- Sliding uterus against middle rectum

### 5. Posterior Compartment – Rectovaginal Deep Endometriosis

#### Deep Endometriosis of Rectum and Vagina



#### Deep Rectal Endometriosis



- Anechoic nodule
- Lack of perfusion

Products mentioned in the material may be subject to government regulations and may not be available in all countries. Shipment and effective sale can only occur after approval from the regulator. Please check with local GE HealthCare representative for details.

© 2024 GE HealthCare. GE is a trademark of General Electric Company used under trademark license.

March 2024 JB28114XX