

Benefits of SonoAVC™ in Assisted Reproductive Medicine Setting



Adela Rodriguez-Fuentes, MD; Jairo Hernandez, PhD; Jean Paul Rouleau, MD; Angela Palumbo, MD, PhD; Centro de Asistencia a la Reproducción Humana de Canarias (FIVAP)

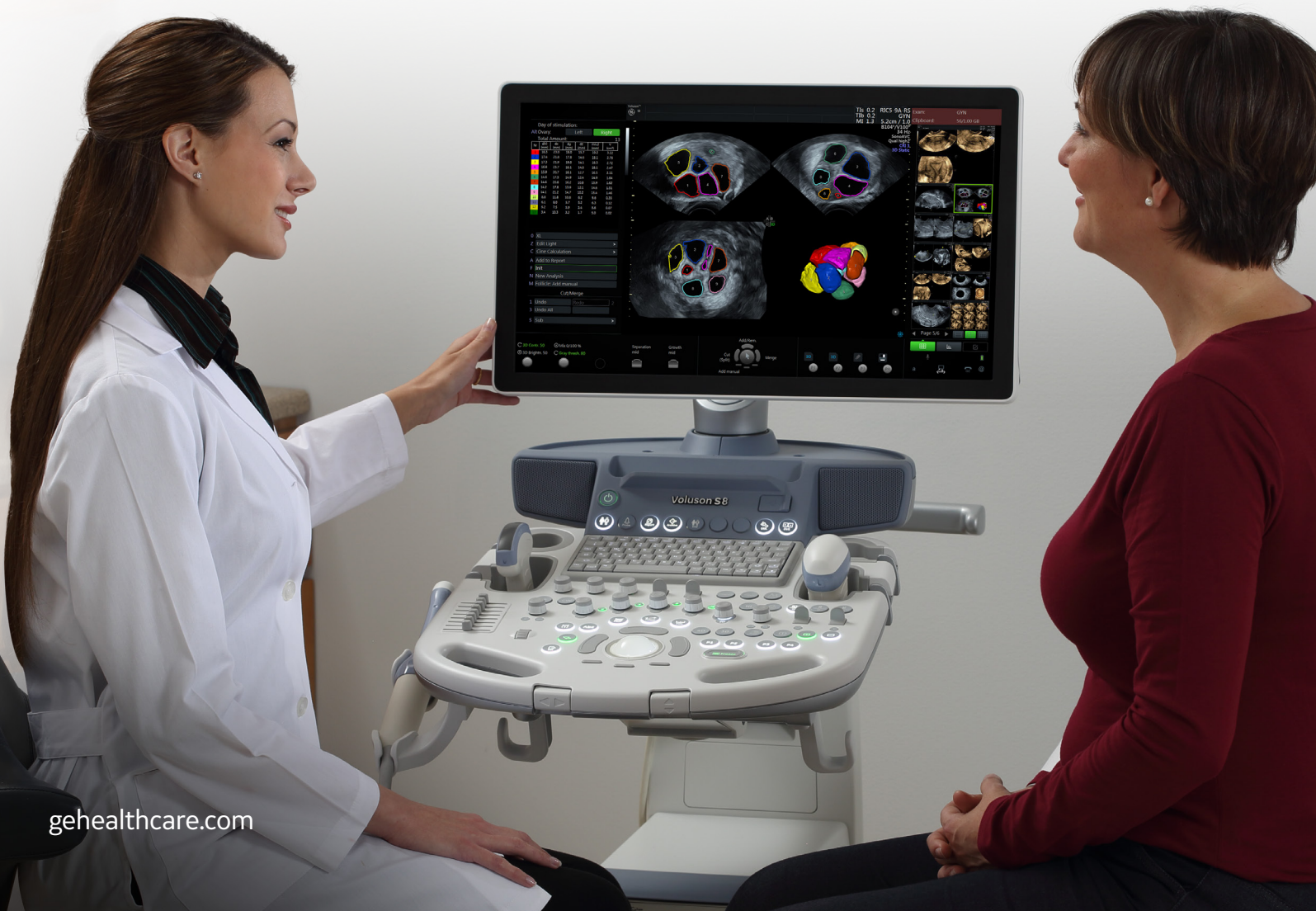WHITE PAPER

Introduction

Imaging methods are constantly being updated and improved, providing clinicians with additional information and modifying previously accepted algorithms. For example, three-dimensional ultrasound (3D US) marked a milestone in gynecologic and obstetric imaging. This is also the case in the In Vitro Fertilization (IVF) setting when looking at the evolution of follicular monitoring.

The classic parameter to determine administration of hCG (human chorionic gonadotropin) to induce oocyte maturation

has been a mean diameter of the leading follicles over 16 to 18 mm on two-dimensional US (2D US). However, back in 1994 Wittmaack and coauthors¹ proposed considering follicle volume instead of mean diameter, focusing on a pool of follicles in the range of maturity rather than on mean diameter. Due to the technology available at that time, the volume was obtained using the two largest diameters and subsequently applying the sphere formula. Follicles between 1 and 7 cc that corresponded to those with a diameter of 12 to 24 mm, showed the best correlation with mature oocytes.



Introduction *(cont.)*

Later on, the development of 3D US allowed the design of specific software to conduct volume calculations using the Virtual Organ Computer-aided Analysis program (VOCAL). Consequently, several publications comparing VOCAL with conventional methods began to arise; Raine-Fenning in 2003 concluded that VOCAL was superior to conventional 2D and 3D volume calculations.² Mercè et al. demonstrated the accuracy of automatic measurements of volume and showed good inter- and intraobserver correlation.³ Shmorgun et al. highlighted that volumes obtained from 3D acquisitions correlated better with oocyte maturity.⁴ However, at that time, volume calculations were still time consuming when applied to stimulated ovaries, making the method unpractical in daily clinical practice.

In 2008, SonoAVC*follicle* became available resolving this issue and allowing automatic follicle counts/volume measurements in a few seconds. This software, developed by GE Healthcare (Zipf, Austria) to assess stimulated ovaries, generates a report that specify the three diameters, the mean diameter and the volume of each follicle in descending order. Moreover, every follicle is color-coded making them easily identifiable in the 3D representation of the ovary.

Several authors have since concluded that SonoAVC is the most accurate technique to assess follicular volume, taking as the gold standard aspirated follicular fluid on the day of egg retrieval.^{5,6}

Clinical application of SonoAVC

In IVF settings, SonoAVC can be used for follicular monitoring during ovulation induction (SonoAVC*follicle*) as well as in pretreatment ovarian evaluation using a specific software known as SonoAVC*antral*.

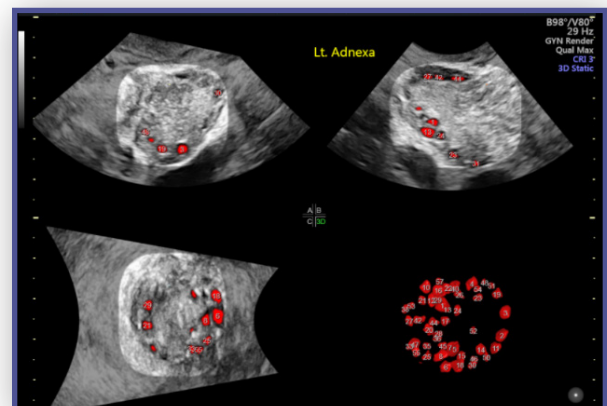
The first to be developed was SonoAVC*follicle*. The software has constantly been updated, leading to progressively improved results in subsequent versions. Over the past ten years, several studies have focused on the potential advantages of automatic follicular monitoring as opposed to manual monitoring showing that:

1. SonoAVC calculations are comparable to manual measurements of 3 diameters from 3D volumes or to VOCAL measurements.^{8,9,10}
2. Follicular volume measured by SonoAVC correlates better with aspirated follicular fluid than VOCAL or 2D measurements.^{5,6}
3. Automatic monitoring saves time in the examination room representing an advantage for both patients and clinicians.^{5,6,8,11}
4. SonoAVC reduces interobserver variability.

While it is clear that SonoAVC is a quick, accurate and reproducible software, a still controversial issue is whether it contributes to improve fertility treatment outcomes. Randomized clinical trials have failed to demonstrate superiority of automated follicular monitoring compared to manual monitoring.¹² Obviously, pregnancy and live birth rates depend on multiple factors including maternal age, embryo quality, cause of infertility, and male factor, besides the number of mature eggs retrieved, so it is not easy to assess the impact of the follicular monitoring technique. Our research^{11,13} suggests that a follicular volume of 0.7 cc has a greater than 85% probability of being associated with a mature egg. Therefore, we believe that follicular volume – the new parameter so easily measured by SonoAVC – gives valuable information during ovarian stimulation that improves individualization of treatment for each patient. This is the reason why we routinely apply this information to make clinical decisions in our center. Research is ongoing in our clinic to evaluate the potential beneficial effect of SonoAVC on IVF success rates. In order to illustrate the benefits of SonoAVC *follicle* in daily clinical practice, we present some clinical cases of ours in **Appendix A**.

The Antral Follicle Count (AFC) is an extremely useful clinical parameter to establish ovarian reserve. While biochemical markers such as basal FSH and estradiol or AMH are still widely used in most practices as indicators of ovarian reserve, AFC correlates very well with the number of oocytes retrieved and is a very user-friendly measurement. However, as any operator-dependent technique, manual AFC is not an objective parameter and ranges of normality are still unclear. Several authors^{14,15} have attempted the use of the original SonoAVC program for the measurement of antral follicle count (AFC). Clearly, a software designed to detect stimulated follicles (large, fluid-filled structures) is not ideal for small antral follicles and a dedicated software with improved detection of small follicles was recently developed (SonoAVC*antral*).¹⁵ Experience with this software is limited and our group is conducting a research project to test applicability to clinical practice. Preliminary results suggest that manual antral follicle count results are significantly different from automatic ones, with good interobserver reproducibility of SonoAVC*antral* results.

Image 1 represents the AFC in a patient with polycystic ovaries



Appendix A

CASE 1:

- Clinical information: 35 year old patient undergoing follicular stimulation for IVF. Preimplantation genetic testing – Aneuploidy (PGT-A) needed
- AFC: 17 follicles on the right ovary and 10 follicles on the left

Figure 1.1

TRATAMIENTO DE INDUCCIÓN DE LA OVULACIÓN PARA FECUNDACIÓN IN VITRO																							
DIAS DEL CICLO	2	3	4	5	6	7	8	9	10	11	12	13	14	15	16	17	18	19	20	21	22	23	24
July 2017	8	9	10	11	12	13	14	15	16	17	18	19	20	21	22	23	24						
ORGALUTRAN							025	025	025	025	025												
MENOPUR	15	15	15	15	150	150	150	150	150	150	150	150											
GONAL	15	15	15	150	150	150	150	150	150	150	150	150											
PROCRIN	0	0	0																				
OTROS																							
Dx: Tubarico																							
ENDOMETRIO 5.3 m																							
RIGHT OVARY																							
LEFT OVARY																							
DATE																							
7.07.2017																							

Fig. 1.1 shows the follicular monitoring patient sheet. As you can observe, on day 12, we had 3 follicles over 18 mm with a progesterone level of 1.14 ng/ml. If we look at the SonoAVC on the same day (Fig. 1.2), there were 13 follicles over 0.7 cc that might be mature at that time. Notice that there were 2 follicles between 0.6 and 0.7 that could reach maturity in one more day.

Since this patient needed Preimplantation Genetic Testing (PGT) and blastocyst vitrification with subsequent cryotransfer, we decided to wait one more day and retrieve as many mature oocytes as possible. In this situation, we could focus our attention on follicular growth without considering a possible worse implantation due to rising progesterone levels. Finally, 15 mature oocytes were retrieved, and 17 follicles were over 0.7 cc on the SonoAVC report of the next day (Fig. 1.3).

Figure 1.2

Seguimiento Follicular (SonoAVC)		Fecha	18.07.2017	Fecha	31.08.2017	Fecha	31.08.2017	Fecha	31.08.2017
Ovario derecho		Nº	D(V)	Dx	Dy	Dz	Dm	Vol	
1	15.1	23.8	13.4	12.0	16.4	1.79			
2	14.9	24.6	15.3	12.4	17.4	1.74			
3	14.9	21.3	16.4	10.5	16.0	1.72			
4	11.9	18.5	11.0	8.9	12.8	0.88			
5	11.4	14.8	11.2	9.3	11.8	0.77			
6	10.8	13.9	11.0	8.7	11.2	0.67			
7	10.8	15.3	10.4	8.9	11.6	0.65			
8	10.4	15.6	11.9	6.4	11.3	0.59			
9	10.2	17.1	11.1	6.7	11.7	0.56			
10	9.4	11.7	9.7	8.0	9.8	0.43			
11	8.6	13.5	8.7	6.0	9.4	0.33			
12	7.7	10.0	7.9	6.2	8.0	0.24			
13	5.9	8.6	6.9	3.7	6.4	0.11			
14	5.7	9.8	6.1	3.8	6.6	0.10			
15	2.9	4.5	3.1	1.9	3.1	0.01			

Figure 1.3

Seguimiento Follicular (SonoAVC)		Fecha	19.07.2017	Fecha	31.08.2017	Fecha	31.08.2017	Fecha	31.08.2017
Ovario derecho		Nº	D(V)	Dx	Dy	Dz	Dm	Vol	
1	17.4	24.7	19.6	13.8	19.4	2.77			
2	16.3	24.4	23.6	11.6	19.9	2.28			
3	15.9	21.6	18.9	11.5	17.3	2.10			
4	13.4	18.9	13.8	9.8	14.2	1.25			
5	12.3	19.2	13.8	7.3	13.4	0.97			
6	12.2	19.9	13.8	7.6	13.8	0.95			
7	11.5	14.9	12.1	8.7	11.9	0.81			
8	11.5	20.3	9.6	9.3	13.1	0.80			
9	11.2	14.4	11.6	8.9	11.6	0.74			
10	10.8	17.5	10.3	7.7	11.8	0.67			
11	10.1	12.5	10.1	9.0	10.5	0.55			
12	9.3	11.4	9.2	8.4	9.6	0.42			
13	7.9	13.0	9.8	4.7	9.1	0.26			
14	6.4	9.2	8.2	3.8	7.1	0.14			
15	3.3	5.3	3.2	2.6	3.7	0.02			

- 25 year old donor
- AFC: 20 follicles on the right ovary and 27 follicles on the left
- On day 12 of stimulation, the classical criteria to trigger ovulation (>2 follicles over 18 mm) was reached but if we look at the SonoAVC report there are a pool of follicles close to the cut-off value for maturity (0.7 cc) so one day more of stimulation may be beneficial to obtain a better rate of mature eggs. In this type of patient with so many follicles, the SonoAVC report gives us an idea of what happens with the follicles on the boundary of maturity

[illegible]

Seguimiento Folicular

Fecha

FUR

07.07.2018

20.06.2018

Diario del ciclo

18

Grosor endometrial

9,6 mm

Medicación

Ovario derecho

Nº	D(V)	Dx	Dy	Dz	Dm	Vol
1	17,8	21,0	19,2	15,6	18,6	2,95
2	17,0	29,0	15,3	14,2	19,5	2,58
3	16,6	27,3	17,7	12,9	19,3	2,38
4	16,4	30,1	17,1	13,3	20,2	2,31
5	16,3	23,6	18,0	12,5	18,1	2,27
6	16,0	21,5	18,1	11,1	16,9	2,14
7	15,8	18,6	17,2	13,8	16,5	2,06
8	15,1	23,5	15,1	11,4	16,7	1,81
9	15,1	30,0	18,3	9,5	19,3	1,80
10	15,0	28,4	14,1	10,3	17,6	1,76
11	14,0	39,4	13,6	7,4	20,1	1,43
12	13,9	22,6	13,9	10,0	15,5	1,40
13	13,9	18,5	14,9	10,6	14,7	1,40
14	13,3	18,0	15,9	9,5	14,5	1,24
15	13,2	23,6	14,0	8,1	15,2	1,21

Ovario izquierdo

Nº	D(V)	Dx	Dy	Dz	Dm	Vol
1	18,2	29,1	15,9	14,8	19,9	3,15
2	17,4	20,7	18,7	15,0	18,2	2,74
3	17,3	37,6	16,7	12,1	22,1	2,72
4	16,7	26,3	15,9	12,1	18,1	2,46
5	16,2	25,6	18,3	14,1	19,3	2,23
6	16,1	25,4	20,6	8,9	18,3	2,17
7	15,5	24,5	16,3	12,2	17,6	1,95
8	15,4	18,1	16,4	13,6	16,0	1,90
9	14,5	21,3	13,8	11,3	15,5	1,61
10	14,5	20,3	15,7	10,9	15,6	1,60
11	14,4	21,0	16,3	11,0	16,1	1,57
12	13,8	19,1	13,4	11,6	14,7	1,39
13	13,7	19,1	14,4	10,7	14,7	1,36
14	13,2	22,1	12,9	9,1	14,7	1,21
15	12,9	18,1	15,6	8,4	14,1	1,13

Diámetros en [mm]

Volúmenes en [mm³]

Comentario

Folículos adicionales...

Imprimir seguimiento folicular (SonoAVC) en el informe

Seguimiento Folicular
(SonoAVC)

Fecha
FUR

06.07.2018
20.06.2018

Día del ciclo
Medicación

17

Grosor endometrial

8,9 mm

Ovario derecho

N°	D[V]	Dx	Dy	Dz	Dm	Vol
1	18,2	27,3	17,8	15,0	20,1	3,15
2	16,3	20,3	17,5	13,3	17,0	2,26
3	14,7	34,1	17,3	7,4	19,6	1,66
4	14,6	18,4	16,5	11,5	15,5	1,64
5	14,4	29,1	17,5	9,7	18,8	1,55
6	13,9	18,5	15,6	9,9	14,7	1,40
7	13,9	28,1	15,0	8,9	17,3	1,40
8	13,6	19,3	13,6	10,6	14,5	1,32
9	12,8	16,2	14,8	10,7	13,9	1,11
10	12,2	17,0	12,4	9,4	12,9	0,96
11	11,9	25,2	12,6	8,7	15,5	0,88
12	11,5	19,9	9,6	9,1	12,8	0,79
13	11,1	16,4	13,7	6,7	12,3	0,72
14	10,9	18,6	11,9	7,1	12,5	0,68
15	10,4	19,6	9,2	7,8	12,2	0,59

Ovario izquierdo

N°	D[V]	Dx	Dy	Dz	Dm	Vol
1	19,3	32,5	19,8	15,9	22,7	3,79
2	18,6	28,2	19,0	15,1	20,8	3,37
3	16,5	26,5	15,7	14,0	18,7	2,35
4	14,8	21,7	13,8	11,5	15,6	1,68
5	14,5	23,3	15,7	12,0	17,0	1,59
6	14,2	21,4	15,1	11,0	15,9	1,51
7	14,2	22,8	18,5	7,8	16,4	1,49
8	14,0	17,9	15,4	11,8	15,1	1,44
9	13,9	16,8	14,4	12,2	14,5	1,42
10	13,9	20,8	16,0	12,5	16,4	1,41
11	12,8	18,4	13,9	9,3	13,9	1,09
12	12,3	17,4	12,6	9,7	13,2	0,97
13	12,2	15,4	14,4	8,7	12,8	0,95
14	12,1	18,1	12,4	9,3	13,3	0,92
15	11,7	18,3	13,0	8,4	13,2	0,83

Díámetros en [mm], Volúmenes en [ml]

Comentario

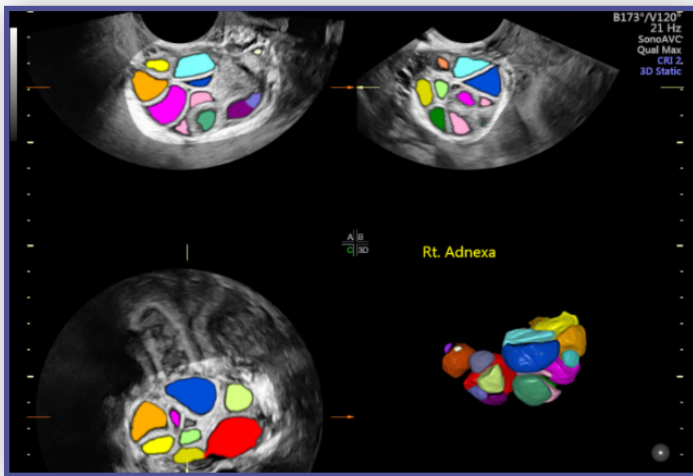
☐ Foliculos adicionales...

☐ Imprimir seguimiento folicular (SonoAVC) en el informe

Folículos adicionales SonoAVC							Ovario derecho							Ovario izquierdo						
N°	D(V)	Dx	Dy	Dz	Dm	Vol	N°	D(V)	Dx	Dy	Dz	Dm	Vol	N°	D(V)	Dx	Dy	Dz	Dm	Vol
16	12,4	15,3	12,1	10,6	12,6	0,99	16	12,6	17,2	12,3	9,8	13,1	1,04	16	12,6	17,2	12,3	9,8	13,1	1,04
17	12,3	18,0	12,7	8,4	13,0	0,97	17	12,3	15,1	12,2	11,1	12,8	0,98	17	12,3	15,1	12,2	11,1	12,8	0,98
18	12,0	26,9	9,9	8,1	15,0	0,90	18	11,1	15,6	12,5	7,9	12,0	0,71	18	11,1	15,6	12,5	7,9	12,0	0,71
19	11,5	15,9	14,4	7,3	12,5	0,80	19	10,5	13,6	12,2	7,3	11,0	0,60	19	10,5	13,6	12,2	7,3	11,0	0,60
20	11,4	15,5	11,6	8,6	11,9	0,77	20	9,9	14,0	12,4	7,7	11,3	0,51	20	9,9	14,0	12,4	7,7	11,3	0,51
21	11,2	17,3	11,9	7,6	12,3	0,74	21	9,9	13,2	11,8	8,3	11,1	0,51	21	9,9	13,2	11,8	8,3	11,1	0,51
22	11,1	23,5	10,6	7,9	14,0	0,72	22	9,4	15,4	8,9	6,7	10,3	0,43	22	9,4	15,4	8,9	6,7	10,3	0,43
23	11,1	14,3	12,9	8,0	11,7	0,71	23	9,3	16,5	9,9	7,4	11,3	0,42	23	9,3	16,5	9,9	7,4	11,3	0,42
24	10,3	15,8	10,3	7,1	11,0	0,57	24	8,4	13,9	9,5	5,1	9,5	0,31	24	8,4	13,9	9,5	5,1	9,5	0,31
25	9,2	13,6	10,1	7,4	10,4	0,41	25	7,9	17,4	9,1	4,1	10,2	0,26	25	7,9	17,4	9,1	4,1	10,2	0,26
26	8,9	13,4	10,5	6,3	10,1	0,37	26	6,4	9,7	7,4	4,1	7,0	0,13	26	6,4	9,7	7,4	4,1	7,0	0,13
27	8,8	11,4	10,6	8,1	10,0	0,36	27	4,1	5,3	4,7	2,9	4,3	0,04	27	4,1	5,3	4,7	2,9	4,3	0,04
28	8,2	15,3	8,9	5,4	9,9	0,29	28	3,6	4,7	4,0	2,7	3,8	0,03	28	3,6	4,7	4,0	2,7	3,8	0,03
29	7,5	11,5	9,3	4,8	8,6	0,22	29	2,5	4,3	2,2	1,9	2,8	0,01	29	2,5	4,3	2,2	1,9	2,8	0,01
30	6,6	9,9	8,3	3,7	7,3	0,15	30							30						
31	6,2	11,3	6,5	4,4	7,4	0,13	31							31						
32	5,9	9,1	7,2	3,4	6,6	0,11	32							32						
33	4,2	5,7	3,8	3,5	4,3	0,04	33							33						
34	4,2	13,4	4,3	1,9	6,5	0,04	34							34						
35	3,1	9,1	3,2	2,2	4,8	0,01	35							35						
36	2,6	3,5	3,3	1,6	2,8	0,01	36							36						

Folículos adicionales SonoAVC							Ovario derecho							Ovario izquierdo						
N°	D(V)	Dx	Dy	Dz	Dm	Vol	N°	D(V)	Dx	Dy	Dz	Dm	Vol	N°	D(V)	Dx	Dy	Dz	Dm	Vol
16	10.8	12.6	10.0	8.3	10.3	0.53	16	11.3	14.3	14.1	7.8	12.1	0.75	17	10.2	15.8	10.9	7.9	11.6	0.55
17	9.9	15.9	9.7	8.5	11.4	0.51	18	10.0	12.8	9.5	8.3	10.2	0.52	19	9.6	12.3	11.0	7.4	10.2	0.46
18	9.7	14.2	10.3	6.6	10.4	0.48	20	9.0	12.0	10.5	6.2	9.6	0.38	21	7.4	15.1	8.5	3.8	9.1	0.21
19	9.2	12.2	9.8	6.9	9.6	0.41	22	6.6	8.9	6.3	5.3	6.8	0.15	23	6.5	8.9	8.4	4.2	7.1	0.15
20	9.0	11.9	10.8	6.3	9.7	0.38	24	2.8	5.3	3.5	2.0	3.6	0.01	25	2.1	9.9	3.1	0.3	4.5	
21	8.6	11.0	9.9	6.1	9.0	0.33	26							27						
22	7.5	11.3	8.7	4.9	8.3	0.22	28							29						
23	7.3	12.1	7.4	4.6	8.0	0.21	30							31						
24	6.4	12.1	6.5	4.1	7.6	0.14	32							33						
25	6.2	8.7	6.2	4.6	6.5	0.12	34							35						
26	5.7	7.6	7.0	4.0	6.2	0.10	36							37						
27	5.5	12.1	6.4	2.6	7.0	0.09	38							39						
28	4.9	8.2	5.1	3.3	5.5	0.06	39							40						
29	4.8	11.1	4.0	3.1	6.1	0.06														
30	4.8	7.7	6.7	2.6	5.7	0.06														
31	4.0	7.5	4.0	2.6	4.7	0.03														
32	3.5	5.8	3.8	2.3	4.0	0.02														
33	2.2	5.7	2.7	1.0	3.1	0.01														
34																				
35																				
36																				
37																				
38																				
39																				
40																				

Image 2



SonoAVC*follicle* use

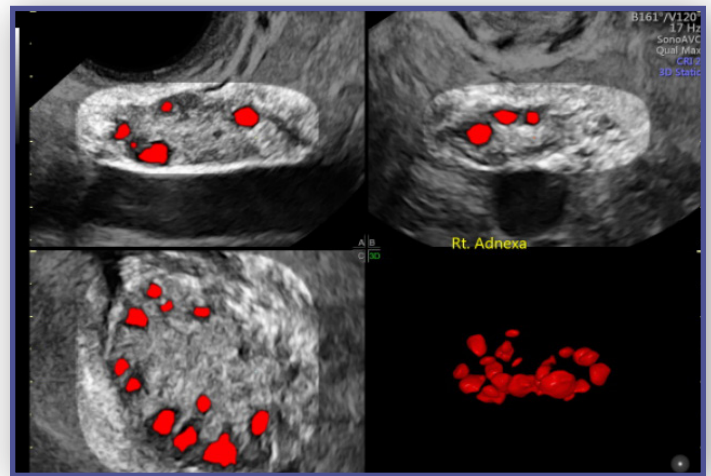
Although there is a learning curve even for trained sonographers, SonoAVC is a very simple tool to use. It is important to remember that 3D US is based on 2D US imaging. That means one must make an effort to optimize the 2D image in order to obtain an adequate 3D volume thereby improving automatic software results and reducing postprocessing work.

After applying SonoAVC*follicle*, in a few seconds, every follicle is represented on the three-dimensional model together with the report on the superior left corner of the screen. Notice that each follicle has the same color code in the report as in the multiplanar view and render mode.

The report includes:

- **d(V)** – Relaxed follicular diameter – what the diameter would be as a sphere, based on the calculated Volume (V), if the follicle was not compressed by surrounding structures
- **dx** – Length of x-axis of best fitting ellipsoid
- **dy** – Length of y-axis of best fitting ellipsoid
- **dz** – Length of z-axis of best fitting ellipsoid
- **mean d** – Follicle mean diameter
- **V** – Follicular volume based on voxel count

Image 3



SonoAVC*antral* use

This is quite a novel software; therefore, there is no published experience on it. SonoAVC*antral* automatically counts the number of antral follicles in the ovary and categorizes results into user defined size groups.

The resulting report provides a short summary of the groups and respective counts, as well as a complete list of each antral follicle measured (including its diameter and volume).

In our experience, it reduces the interobserver variability on AFC being its results different from manual counts with statistical significance. Thus, it may help to make pretreatment evaluation of ovarian reserve more accurate with what presumably could better predict fertility treatment outcomes. We are working in this direction to demonstrate our hypothesis.

About Centro de Asistencia a La Reproducción Humana de Canarias

Centro de Asistencia a La Reproducción Humana de Canarias is a private clinic located in Tenerife, the largest of the Canary Islands. We serve a varied patient population including locals, patients living in the peninsula and foreign patients, mainly from Italy, but also from the rest of Europe and the USA. We have a successful IVF program including about 500 fertility treatments a year. We consider 3D US an invaluable tool for the diagnosis and treatment of infertile women. We perform numerous ultrasound exams for evaluation of ovarian reserve and sonohysterograms. Moreover, we perform gynecologic exams from puberty to menopause and we follow normal and high-risk pregnancies. We perform about 200 fertility and gynecologic surgeries a year. Our staff includes 4 full time and several part time gynecologists, two radiologists, anesthesiologists and then nurses, embryologists and ancillary staff.

Angela Palumbo is a US trained (Yale University and Harvard University), board-certified reproductive endocrinologist who has dedicated her career to both research and clinical work, with numerous resulting publications in both basic and clinical sciences. She is the founder and medical director of Centro de Asistencia a la Reproducción Humana de Canarias.

Jairo Hernandez is a PhD with an interest in both basic and clinical research related to IVF. He has obtained the ESHRE certification of Senior Embryologist and has been the Director of the IVF Laboratory since 2005. He has published several papers, both basic and clinical and contributed to international meetings with numerous abstracts.

Adela Rodriguez-Fuentes is a radiologist at the Hospital Universitario de Canarias and at Centro de Asistencia a la Reproducción Humana de Canarias. She has shown a special interest in gynecological three-dimensional ultrasound since her first year of residency and has had the opportunity to present her research at several international meetings. She has authored several papers on SonoAVC. She is currently pursuing a PhD at the Universidad de La Laguna in Tenerife.

Jean Paul Rouleau is an Obstetrician Gynecologist and Infertility specialist with expertise in three-dimensional ultrasound and minimally invasive reproductive surgery. He has participated to several national and international meetings and contributed to several peer reviewed articles.

References

1. Wittmaack FM, Kreger DO, Blasco L, Tureck RW, et al. Effect of follicular size on oocyte retrieval, fertilization, cleavage, and embryo quality in in vitro fertilization cycles: a 6-year data collection. *Fertil Steril* 1994; 62: 1205-1210.
2. Raine-Fenning NJ, Campbell BK, Clewes JS, Johnson IR. The interobserver reliability of ovarian volume measurement is improved with three-dimensional ultrasound, but dependent upon technique. *Ultrasound Med Biol* 2003;29:1685-90.
3. Luis T, Mercé, Gomez B, Engels V, Bau S, Bajo JM. Intraobserver and interobserver reproducibility of ovarian volume, antral follicle count, and vascularity indices obtained with transvaginal 3-dimensional ultrasonography, power doppler angiography, and the virtual organ computer-aided analysis imaging program. *J Ultrasound Med* 2005 May; 24: 1279-87.
4. Shmorgun D, Hughes E, Mohide P, Roberts R. Prospective cohort study of three-versus two dimensional ultrasound for prediction of oocyte maturity. *Fertil Steril*. 2010 March; (93):1333-1337.
5. Raine-Fenning N, Deb S, Jayaprakasan K, Clewes J, Hopkisson J, Campbell B. Timing of oocyte maturation and egg collection during controlled ovarian stimulation: a randomized controlled trial evaluating manual and automated measurements of follicle diameter. *Fertil Steril* 2010 June; 94: 184-188.
6. Salama S, Arbo E, Lamazou F, Levaillant JM, Frydman R, Fanchin R. Reproducibility and reliability of automated volumetric measurement of single preovulatory follicles using SonoAVC. *Fertil Steril* 2010 April; (93): 2069-2073.
7. Rodriguez A, Guillén JJ, López MJ, Vassena R, Coll O, Vernaev V. Learning curves in 3-dimensional sonographic follicle monitoring during controlled ovarian stimulation. *J Ultrasound Med*. 2014 Apr; 33:649-55.
8. Deutch T, Joergner I, Matson D, Oehninger S, Bocca S, Hoenigmann et al. Automated assessment of ovarian follicles using a novel three-dimensional ultrasound software. *Fertil Steril* Nov; 92: 1562-1568.
9. Lamazou F, Arbo E, Salama S, Grynberg M, Frydman R, Fanchin, R. Reliability of automated volumetric measurement of multiple growing follicles in controlled ovarian hyperstimulation. *Fertil Steril* Nov; (94): 2172-2176.
10. Ata B, Seyhan A, Reinblatt SL, Shalom-Paz E, Krishnamurthy S, Tan SL. Comparison of automated and manual follicle monitoring in an unrestricted population of 100 women undergoing controlled ovarian stimulation for IVF. *Human reproduction* 2010 Nov; 26: 127-133.
11. Rodríguez-Fuentes A, Hernández J, García-Guzmán R, China E, Iaconianni L, Palumbo A. Prospective evaluation of automated follicle monitoring in 58 in vitro fertilization cycles: follicular volume as a new indicator of oocyte maturity. *Fertil Steril* Jan; (93): 616-620.
12. Raine-Fenning N, Deb S, Jayaprakasan K, Clewes J, Hopkisson J, Campbell B. Timing of oocyte maturation and egg collection during controlled ovarian stimulation: a randomized controlled trial evaluating manual and automated measurements of follicle diameter. *Fertil Steril* 2010 June; 94: 184-188.
13. Hernández J, Rodríguez-Fuentes A, Puopolo M, Palumbo A. Follicular Volume Predicts Oocyte Maturity: A Prospective Cohort Study Using Three-Dimensional Ultrasound and SonoAVC. *Reprod Sci*. 2016 Dec; (23):1639-1643.
14. Deb S, Jayaprakasan K, Campbell BK, Clewes JS et al. Intraobserver and interobserver reliability of automated antral follicle counts made using three-dimensional ultrasound and SonoAVC. *Ultrasound Obstet Gynecol*. 2009 Feb; 33:477-83.
15. Deb S, Campbell BK, Clewes JS, Raine-Fenning NJ. Quantitative analysis of antral follicle number and size: a comparison of two-dimensional and automated three-dimensional ultrasound techniques. *Ultrasound Obstet Gynecol* 2010; 35: 354-360.

Imagination at work

© 2019 General Electric Company - All rights reserved.

GE Healthcare reserves the right to make changes in specifications and features shown herein, or discontinue the product described at any time without notice or obligation. Contact your GE Healthcare representative for the most current information. GE, GE Monogram, and SonoAVC are trademarks of General Electric Company. GE Healthcare, a division of General Electric Company. GE Medical Systems, Inc., doing business as GE Healthcare.

January 2019
JB63024XXa

