

ONE-VISIT INFERTILITY WORKUP

A Protocol for 3D Ultrasound Assessment

Jean Paul Rouleau, MD; Adela Rodriguez, MD; Manuela Costa, CNM; Angela Palumbo, MD, PhD, FACOG
Centro de Asistencia a la Reproducción Humana de Canarias, Tenerife, Spain



The availability of 3D ultrasound has greatly improved our diagnostic capability and enabled an expeditious and thorough evaluation of infertility patients during the first visit. With a simple volume acquisition of the uterus and ovaries, then subsequent image reconstruction and postprocessing, significant information can be obtained about possible factors affecting fertility.



Initial Telemedicine Consultation

- Patient history completed
- Explanation of clinic visit and diagnostic process



Clinic visit
scheduled on
day 7-10 of
menstrual cycle



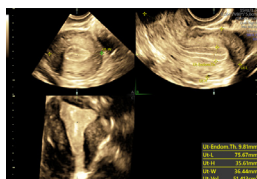
3D US with Comprehensive Pelvic Exam

- 3D assessment of uterus
- 3D antral follicle count (AFC)
- 3D sonohysterogram/virtual hysteroscopy HyCoSy

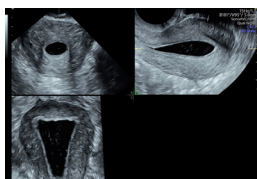
Semen analysis and blood tests as needed

ASSESSMENT OF THE UTERUS: 3D ULTRASOUND AND SONOHYSTEROGRAM

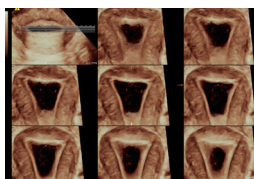
Views obtained from a single volume acquisition demonstrate information equivalent to MRI or a CT scan. The details of the uterine cavity are enhanced by advanced, easy to use 3D rendering techniques.



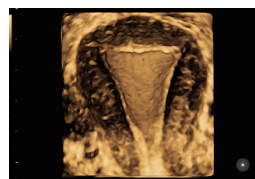
3D Multiplanar Reconstruction



Saline Infusion Sonohysterogram



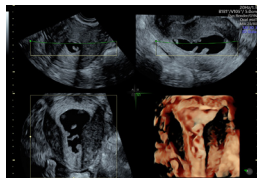
Tomographic Ultrasound Imaging



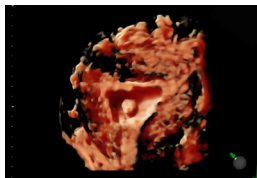
Virtual Hysteroscopy

UTERINE PATHOLOGY OR ABNORMALITIES

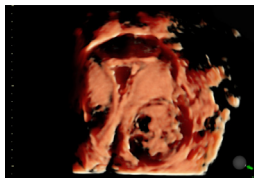
By performing a sonohysterogram on the same day, we are able to do a thorough assessment of the uterine cavity. Saline solution is used to distend the uterine cavity and a volume acquired.



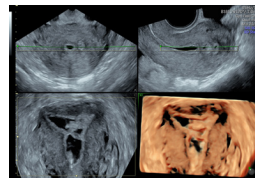
Sonohysterogram (SHG) – polyp



HDlive™ SHG – polyp



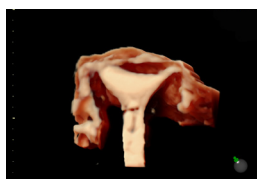
HDlive SHG – myoma



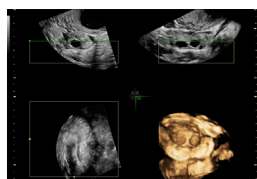
SHG – Asherman's syndrome

ASSESSMENT OF FALLOPIAN TUBES

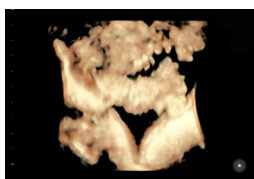
After evaluating the uterine cavity, a sonosalpingogram is done to assess the fallopian tubes, using either a saline solution mixed with air or ExEm® Foam.



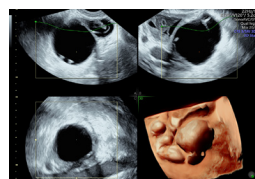
HDlive normal tubes after
HyFoSy with ExEm foam



Tortuous fallopian tube adhered
to ovary



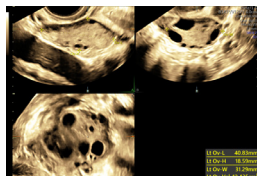
Air, saline sonosalpingogram of
tortuous fallopian tube



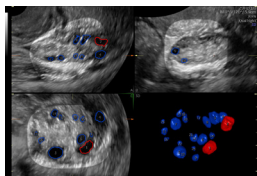
Sonosalpingogram of
hydrosalpinx

ASSESSMENT OF OVARIES

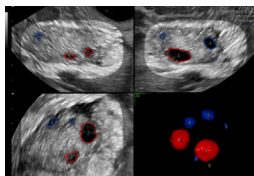
During the initial visit it is important to evaluate ovarian reserve. In our center we use 3D ultrasound with the addition of the SonoAVC™ antral tool to easily and efficiently assess ovarian reserve.



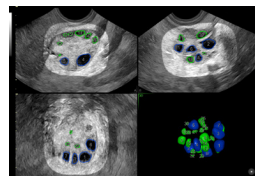
Volume Contrast Imaging



Normal ovarian reserve

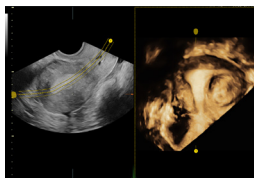


Poor ovarian reserve

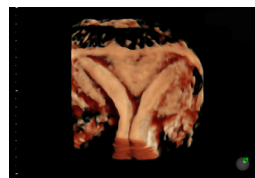


Polycystic ovaries

A high percentage of infertile women have uterine, ovarian or tubal abnormalities or pathology which can easily be diagnosed by ultrasound. The addition of 3D with advanced rendering techniques can provide more diagnostic information and greater detail. This enables us to have all the data available to plan for next steps and develop a plan of action for our patients after their initial visit. Patients have found this comfortable and convenient.



Uterine Trace provides coronal
plane in a few easy steps



HDlive uterine didelphys





© GE 2021

GE, the GE Monogram, HD*live* and SonoAVC are trademarks of GE.
ExEm® is a registered trademark of GISKIT B.V.
September 2021 JB16866XX

Scan QR code to watch video
demonstrating the **one-visit**
infertility protocol

